

CASE STUDY

- 100% WOUND REDUCTION
- TOTAL HEALING IN 14 WEEKS
- 11 ACTIGRAFT APPLICATIONS

PATIENT:

89 year-old, female.

PAST MEDICAL HISTORY:

Atrial Fibrillation, Anemia

LABS:

WBC 9, RBC 3.46, Hgb 9.9, Hct 30.2, MCV 87.4

WOUND HISTORY:

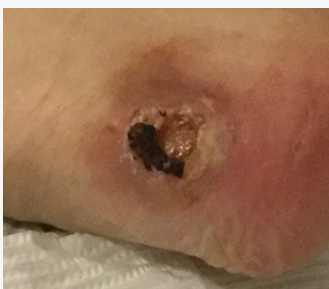- R. Posterior Heel Pressure Ulcer Stage 3
- 4 Month Old Ulcer
- 1 cm X 1.2 cm X 0.1 cm, Light Serous/Sanguineous
- ABI Results for the Affected Leg = 0.75

PAST TREATMENTS:

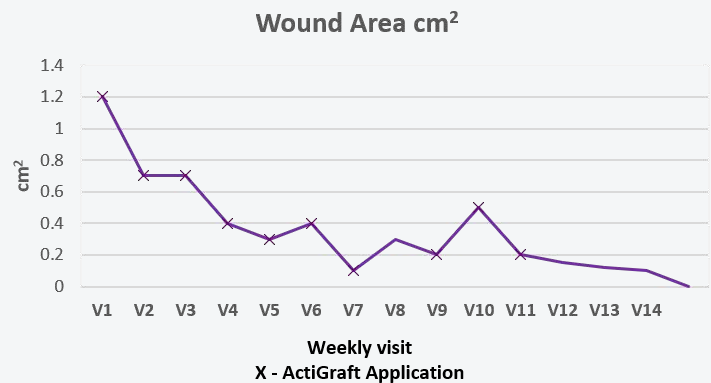
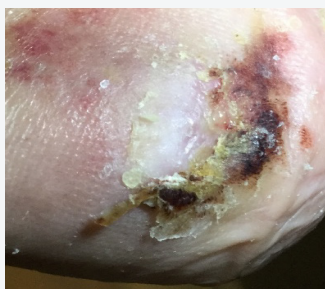Santyl

ACTIGRAFT TREATMENT PROGRESSION:

Day 0



Day 98



V=Weekly Application

OFFLOADING:

Offloading boot